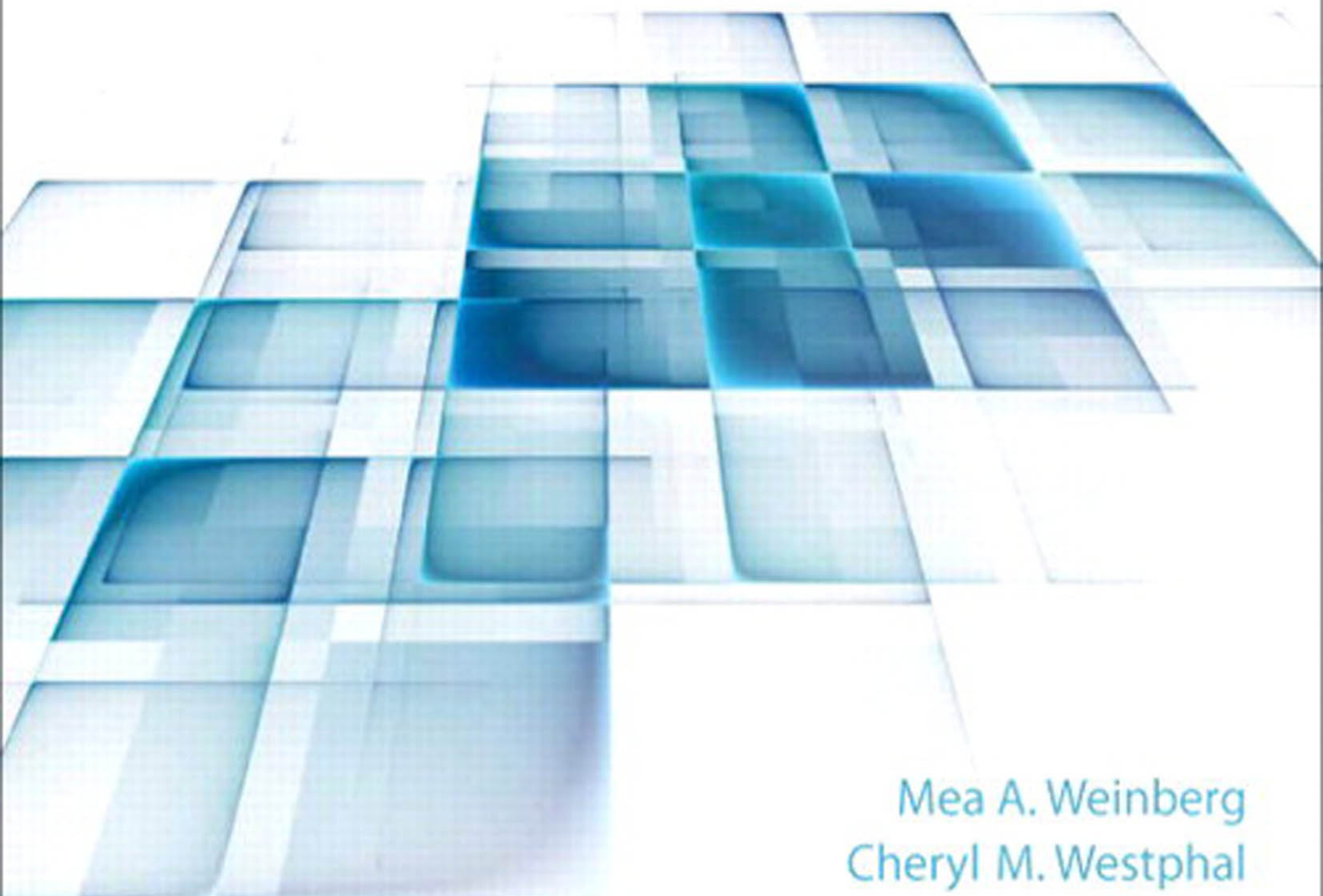


COMPREHENSIVE PERIODONTICS

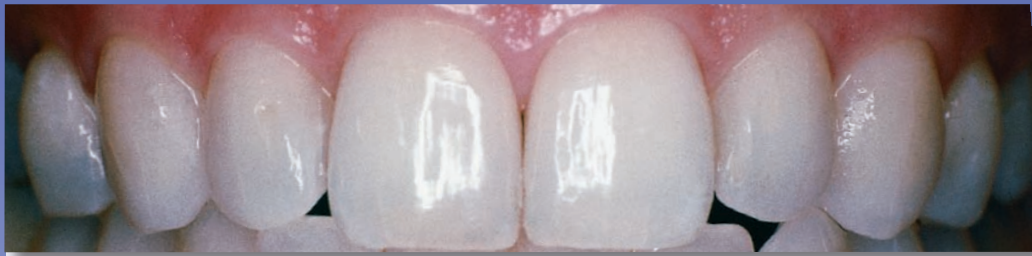for the Dental Hygienist

Fourth Edition



Mea A. Weinberg
Cheryl M. Westphal
Stuart J. Froum
Stuart L. Segelnick

COMPREHENSIVE PERIODONTICS FOR THE DENTAL HYGIENIST



FOURTH EDITION

Mea A. Weinberg, D.M.D., M.S.D., R.Ph.

Cheryl M. Westphal Theile, Ed.D., R.D.H.

Stuart J. Froum, D.D.S.

Stuart L. Segelnick, D.D.S., M.S.

New York University College of Dentistry
New York, New York

Pearson

Boston Columbus Indianapolis New York San Francisco Upper Saddle River Amsterdam
Cape Town Dubai London Madrid Milan Munich Paris Montreal Toronto Delhi Mexico City Sao Paulo
Sydney Hong Kong Seoul Singapore Taipei Tokyo

Notice: The authors and the publisher of this volume have taken care that the information and technical recommendations contained herein are based on research and expert consultation, and are accurate and compatible with the standards generally accepted at the time of publication. Nevertheless, as new information becomes available, changes in clinical and technical practices become necessary. The reader is advised to carefully consult manufacturers' instructions and information material for all supplies and equipment before use, and to consult with a healthcare professional as necessary. This advice is especially important when using new supplies or equipment for clinical purposes. The authors and publisher disclaim all responsibility for any liability, loss, injury, or damage incurred as a consequence, directly or indirectly, of the use and application of any of the contents of this volume.

Publisher: Julie Levin Alexander
Assistant to Publisher: Regina Bruno
Editor-in-Chief: Marlene McHugh Pratt
Executive Acquisitions Editor: John Goucher
Program Manager: Nicole Ragonese
Editorial Assistant: Erica Viviani
Director of Marketing: David Gesell
Executive Marketing Manager: Katrin Beacom
Senior Marketing Coordinator: Alicia Wozniak
Media Program Manager: Amy Peltier
Media Project Manager: Lorena Cerisano

Project Management Lead: Cynthia Zonneveld
Project Manager: Christina Zingone-Luethje
Production Editor: Patty Donovan, Laserwords
Operations Specialist: Nancy Maneri-Miller
Senior Art Director/Interior: Maria Guglielmo
Creative Director: Jayne Conte
Art Director/Cover: Bruce Kenselaar
Composition: Laserwords Private Limited
Printer/Binder: Courier/Kendallville
Cover Printer: Moore Langen
Cover Image: © DrHitch / Fotolia

Credits and acknowledgments for content borrowed from other sources and reproduced, with permissions, appear on page of this textbook.

Copyright © 2015, 2010, 2006 by Pearson Education, Inc., 1 Lake Street, Upper Saddle River, New Jersey 07458. Publishing as Pearson. All rights reserved. Manufactured in the United States of America. This publication is protected by Copyright, and permission should be obtained from the publisher prior to any prohibited reproduction, storage in a retrieval system, or transmission in any form or by any means, electronic, mechanical, photocopying, recording, or likewise. To obtain permission(s) to use material from this work, please submit a written request to Pearson Education, Inc., Permissions Department, 1 Lake Street, Upper Saddle River, New Jersey 07458.

Library of Congress Cataloging-in-Publication Data

Weinberg, Mea A., author.
Comprehensive periodontics for the dental hygienist /
Mea A. Weinberg, Cheryl Westphal Theile, Stuart J. Froum,
Stuart L. Segelnick. — Fourth edition.
p. ; cm.
Preceded by Comprehensive periodontics for the dental hygienist /
Mea A. Weinberg . . . [et al.] ; consulting editor, James Burke Fine.
3rd ed. c2010.
Includes bibliographical references and index.
ISBN-13: 978-0-13-307772-8
ISBN-10: 0-13-307772-1
I. Theile, Cheryl M. Westphal, author. II. Froum, Stuart J., author.
III. Segelnick, Stuart L., author. IV. Title.
[DNLM: 1. Periodontal Diseases. WU 240]
RK361
6176'32--dc23

2013035040



www.pearsonhighered.com

10 9 8 7 6 5 4 3 2 1
ISBN-13: 978-0-13-307772-8
ISBN-10: 0-13-307772-1

CONTENTS

Foreword v
Preface vii
Contributors ix
Reviewers xi

PART I PERIODONTAL DISEASES: INTRODUCTION AND BACKGROUND 1

- 1 Anatomy of the Periodontal Structures: The Healthy State 2
- 2 Epidemiology of Periodontal Diseases 23
- 3 Dental Biofilm: The Microbiology of the Periodontium in Health and Disease 46
- 4 Bacteria and the Host Response: Inflammatory and Immunology Fundamentals 57
- 5 Local Contributory Factors for Periodontal Diseases 72
- 6 The Oral–Systemic Disease Connection 83

PART II PERIODONTAL DISEASES: CLASSIFICATION 101

- 7 Gingival Diseases 102
- 8 Periodontitis and Other Periodontal Conditions 117
- 9 Necrotizing Periodontal Diseases 135
- 10 Occlusal Trauma 142
- 11 Abscesses of the Periodontium 158

PART III PERIODONTAL DISEASES: THE ASSESSMENT PHASE 167

- 12 Dental Hygiene Process of Care for the Patient with Periodontal Disease 168
- 13 Patient History 173
- 14 Clinical Examination: Extraoral/Intraoral Examination and Dental Evaluation 179
- 15 Clinical Examination: Gingival Assessment 190
- 16 Clinical Examination: Periodontal Assessment 200
- 17 Radiographic Assessment 221
- 18 Advances in Detecting and Monitoring Periodontal Diseases 234

PART IV PERIODONTAL DISEASES: TREATMENT PLANNING, IMPLEMENTATION, AND EVALUATION PHASE 243

- 19 Problem-/Evidence-Based Treatment Planning 244
- 20 Oral Hygiene for the Periodontal Patient: Beyond the Basics 267
- 21 Response to Nonsurgical Therapy 296
- 22 Periodontal Maintenance Therapy 310
- 23 Topical Drug Delivery Systems: Oral Rinses and Irrigation 321
- 24 Systemic and Local Drug Delivery Systems: Systemic Antibiotics, Local Drug Devices, and Enzyme Suppression Therapy 333
- 25 Principles of Periodontal Surgery: Gingivectomy, Osseous Resection, and Periodontal Plastic Surgery 348
- 26 Principles of Periodontal Surgery: Periodontal Regeneration 378
- 27 Implantology 397

PART V CASE STUDIES 421

- Case Study I 422
- Case Study II 427
- Case Study III 433
- Case Study IV 438

Appendices

- A Periodontal Information Resources 447
- B Reading the Literature 449
- C Antibiotic Prophylaxis 451
- D Periodontal Conditions and Smoking 453

Glossary 457
Answers to Self-Quiz Questions 471
Index 473

This page intentionally left blank

FOREWORD

There is no subject of greater importance to the practice of dental hygiene than periodontology. *Comprehensive Periodontics for the Dental Hygienist* by Weinberg and colleagues offers an exceptional opportunity to learn this pivotal aspect of clinical practice at its best. This text accomplishes several important goals in thoughtful and compelling ways: It fosters an evidence-based approach—one that has become central to all clinical disciplines. It cultivates in the practitioner an identity as a person of science—that is, as a sophisticated *consumer* of research. Whereas scientists are assigned the responsibility of generating new knowledge, every practitioner must see him- or herself as a consumer of such information, capable of assessing and critiquing it for him- or herself. The text also underscores the interrelationship between oral disease and systemic health while helping prepare the dental hygienist to cope with increasingly complex technologies and innovations.

The attentive student has much to gain from the text's format, including the convenient use of outlines, goals, statements of educational objectives, inclusion of

key words, reference to relevant websites, and use of self-assessment quizzes. Extraordinary knowledge of the field is available to the student of dental hygiene who is willing to invest time and effort exploiting the opportunities this text affords.

Periodontology is a discipline with a strong scientific base. A flavor of the richness of the underlying literature is reflected in the citations at the end of each chapter. Thus students and practitioners have at their disposal the means to secure a more in-depth treatment of specific topic areas by accessing the foundational literature on which the text is based. Those who do so can become adept at interpreting that literature for themselves, developing in the process the tools they will need to think independently and to remain current in their discipline with the passage of time.

Charles N. Bertolami
Professor and Herman Robert Fox Dean
College of Dentistry
New York University

This page intentionally left blank

PREFACE

There is a significant body of knowledge about the risk factors, pathogenesis, treatment, and prevention of periodontal diseases. This knowledge is rarely applied as an evidence-based approach to the difficult problem of deciding when specific treatments or examination methods are appropriate. Classic and current references are included in each chapter, along with applicable websites so the reader can supplement information in the textbook with information from other sources.

This basic text has been written in an attempt to make the professions' understanding of periodontal diseases accessible to the dental hygiene student, the practicing dental hygienist, and the dentist needing to update their knowledge through a concise synopsis of clinical periodontics.

Part I deals with the anatomy of the periodontium, risk (markers) factors (e.g., dental biofilm, smoking, and diabetes mellitus) for periodontal diseases, and periodontal disease as a potential risk factor for systemic conditions (the periodontal–medicine relationship) such as stroke, cardiovascular disease, and respiratory conditions. This interrelationship between medicine and periodontology has opened new insights into the concept of oral health being an integral part of the overall general and systemic health of an individual. Oral and intravenous bisphosphonates are discussed as they relate to osteonecrosis of the jaw (ONJ).

Part I also reviews the etiology of periodontal diseases including oral biofilm, the bacterial and host response, and periodontal–systemic connection.

Part II discusses in detail the different periodontal diseases according to the most current Classification System of the Periodontal Diseases (American Academy of Periodontology).

Part III deals with the clinical assessment phase of the dental hygiene process of care. This part discusses the

various assessment tools that are required to be performed on a patient for the development of a dental hygiene diagnosis.

Part IV discusses the treatment planning, implementation, and evaluation process of dental hygiene care. Nonsurgical and surgical therapy through problem-based learning (PBL) are discussed in detail. A problem-based system with basic concepts of treatment planning will be introduced to the student. A comprehensive review of halitosis is presented. In this section is an extensive review of drugs used in periodontal therapy, including various controlled-release drug devices (e.g., Arestin®) and enzyme suppression drugs (e.g., doxycycline 20 mg). An expanded section on surgery and implants is included with many color images.

Part V reviews four in-depth periodontal cases with extensive discussion of answers.

The appendices include a comprehensive listing of periodontic informatics, how to critically assess the periodontal literature, and smoking cessation therapy.

At the end of each chapter are board-type questions including new item type formats such as multiple correct answers, extended matching, and ordering which have now been introduced on the National Board Dental Hygiene Examinations. Included in the textbook are four problem-oriented, evidence-based case studies. Each case details the problem, followed by a discussion of the questions and answers to the problem. “Rapid Dental Hints” remind students about key information or a task that should be performed related to the topic discussed. In addition, there are “Did You Know?” comments found within all chapters that provide whimsical information on the topic at hand.

We hope this book will serve as a helpful text for all dental practitioners.

Mea A. Weinberg, D.M.D., M.S.D., R.Ph.

This page intentionally left blank

CONTRIBUTORS

Mary Elizabeth Aichelmann-Reidy, D.D.S.

Assistant Professor, Department of Periodontics
University of Maryland
Baltimore, Maryland

Khalid Almas, B.D.S., M.Sc.
Associate Professor, Division of Periodontology, School of Dental Medicine

University of Connecticut
Farmington, Connecticut

Sangeetha Chandrasekaran, B.D.S.,
Masters Biomedical Sciences, Masters in Oral Sciences

Assistant Professor
Department of Surgical Dentistry
University of Colorado School of Dental Medicine
Aurora, Colorado

Denise Estafan, D.D.S., M.S.

Associate Professor and Director of Clinical Esthetics
Department of Cariology and Comprehensive Care
New York University College of Dentistry
New York, New York

James Burke Fine, D.M.D.

Associate Dean of Postgraduate Studies
Associate Professor of Clinical Dentistry
Director of Postgraduate Periodontics
Columbia University College of Dental Medicine
New York, New York

Cynthia Fong, R.D.H., M.S.

Lecturer/Instructor in Periodontics
Department of Dental Hygiene
Pierce College
Tacoma, Washington

Herbert Frommer, D.D.S.

Professor and Director of Radiology
New York University College of Dentistry
New York, New York

Stuart J. Froum, D.D.S.

Clinical Professor, Director of Research
Department of Periodontology and Implant Dentistry
New York University College of Dentistry
New York, New York

Rosemary DeRosa Hays, R.D.H., M.S.

Clinical Associate Professor, Dental Hygiene Program
New York University College of Dentistry
New York, New York

Debra Jacobowitz, D.D.S.

(Candidate 2014)
New York University College of Dentistry
New York, New York

Judith Kreismann, R.D.H., B.S., M.S.

Clinical Associate Professor, Dental Hygiene Program
New York University College of Dentistry
New York, New York

Josephine Lomangino-Cheung,

D.D.S., M.S.
Clinical Assistant Professor
Department of Cariology and Comprehensive Care
New York University College of Dental Medicine
New York, New York

Eva M. Lupovici, R.D.H., M.S.

Clinical Associate Professor, Dental Hygiene Program
New York University College of Dentistry
New York, New York

Deborah M. Lyle, R.D.H., B.S., M.S.

Director of Professional & Clinical Affairs
Water Pik, Inc.
Morris Plains, New Jersey

John D. Mason, B.A., D.D.S.

Associate Professor, Department of Periodontics
Director of Predoctoral Periodontics
Louisiana State University School of Dentistry
New Orleans, Louisiana

Trisha E. O'Hehir, R.D.H., B.S.

Editor of Perio Reports
Senior Consulting Editor, RHD Magazine
Vice President, Perio-Data™ Company
Assistant Visiting Professor Northern Arizona University
Flagstaff, Arizona

Toula A. Palaiologou, D.D.S., M.S.

Director of Postgraduate Periodontics
Louisiana State University School of Dentistry
New Orleans, Louisiana

Scott W. Podell, D.M.D., M.P.H.

Group Practice Director
Clinical Assistant Professor
Department of Cariology and Comprehensive Care
New York University College of Dentistry
New York, New York

Charles A. Powell, D.D.S., M.S.

Chair, Division of Periodontics and Director of Postgraduate Periodontics
University of Colorado School of Dental Medicine
Aurora, Colorado

Jill Rethman, R.D.H., B.A.

Visiting Clinical Instructor, Department of Dental Hygiene
Editorial Director Dimensions of Dental Hygiene
University of Pittsburgh
Pittsburgh, Pennsylvania
2012 President Hawaii's Dental Hygienists' Association

Michael P. Rethman, D.D.S., M.S.

Past President of the American Academy of Periodontology
Former Chief of Periodontics
Tripler Medical Center
Honolulu, Hawaii

Paul S. Rosen, D.M.D., M.S.

Full-time Periodontic Practice, Yardley, Pennsylvania
Clinical Associate Professor of Periodontics
University of Maryland Dental School
Baltimore, Maryland

Stuart L. Segelnick, D.D.S., M.S.

Clinical Associate Professor
Department of Periodontology and Implant Dentistry
New York University College of Dentistry
New York, New York

Surendra Singh, D.D.S., M.S.

Professor, Department of Periodontics
University of Medicine and Dentistry of New Jersey School of Dentistry
Newark, New Jersey

Jeanine Stabulas-Savage, R.D.H., B.S.,
M.P.H.
Clinical Assistant Professor
Oral and Maxillofacial Pathology, Radiol-
ogy and Medicine
New York University College of
Dentistry
New York, New York

Mea A. Weinberg, D.M.D., M.S.D.,
R.Ph.
Clinical Associate Professor and Director
of Second Year Periodontics
Department of Periodontology and
Implant Dentistry
New York University College of
Dentistry
New York, New York

Cheryl M. Westphal Theile, Ed.D.,
R.D.H.
Clinical Associate Professor and Assistant
Dean for Allied Health Programs
Director, Dental Hygiene Program
New York University College of
Dentistry
New York, New York

Pinelopi Xenoudi, D.D.S., M.S.
Assistant Professor
Surgical Dentistry
University of Colorado School of Dental
Medicine
Aurora, Colorado

Raymond A. Yukna, D.M.D., M.S.
Professor, Directory Periodontic Resi-
dency Program
University of Colorado School of Dental
Medicine Aurora, Colorado

*Selected Illustrations by Jesse Doscher,
D.D.S.*

*Selected Photographs Courtesy of
Dr. John Eum, Dr. James Fine, Dr. Xiu
Yan Li, Dr. Jacqueline Plemmons,
Dr. Jesse Sorrentino, Dr. Michael Turner,
and Dr. Harvey Wishe.*

REVIEWERS

Karmen Aplanalp, R.D.H., B.S.D.H.,
M.Ed.
College of Southern Nevada
Henderson, Nevada

Catherine Boos, D.M.D.
Camden Community College
Camden, New Jersey

Barbara Bush, R.D.H., M.S.Ed.
Western Kentucky University
Bowling Green, Kentucky

Paula E. Covert, C.D.A., R.D.H.,
B.S.D.H.
Asheville-Buncombe Technical
Community College
Asheville, North Carolina

Sheree Duff, R.D.H., M.S.
Baker College of Auburn Hills
Auburn Hills, Michigan

Laura Joseph, R.D.H., M.S., Ed.D.
State University of New York at
Farmingdale
Farmingdale, New York

Tricia Moore, R.D.H.
Northern Arizona University
Flagstaff, Arizona

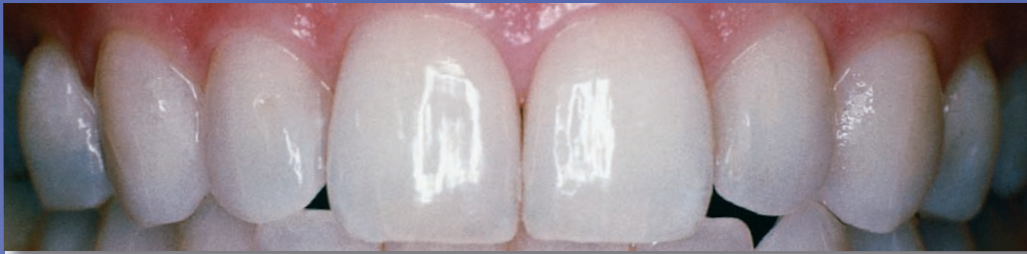Kemaly Parr, R.D.H., M.D.H.
Columbus Technical College
Columbus, Georgia

Shelly A. Purtell, R.D.H., Ph.D.
Broome Community College
Binghamton, New York

Rebecca Smith, R.D.H., A.S.D.H.,
B.H.S.A., M.P.H., Ed.D.
Miami Dade College
Miami, Florida

This page intentionally left blank

Periodontal Diseases: Introduction and Background



OUTLINE

- Chapter 1** Anatomy of the Periodontal Structures: The Healthy State
- Chapter 2** Epidemiology of Periodontal Diseases
- Chapter 3** Dental Biofilm: The Microbiology of the Periodontium in Health and Disease
- Chapter 4** Bacteria and the Host Response: Inflammatory and Immunology Fundamentals
- Chapter 5** Local Contributory Factors for Periodontal Diseases
- Chapter 6** The Oral–Systemic Disease Connection

Anatomy of the Periodontal Structures: The Healthy State

Mea A. Weinberg and Debra Jacobowitz

OUTLINE

Clinical Anatomy of the Gingival Unit
 Microscopic Anatomy of the Gingival Unit
 Attachment Apparatus
 Physiology of the Periodontium
 Changes with Aging
 Dental Hygiene Application
 Key Points
 Self-Quiz
 Case Study
 References

EDUCATIONAL OBJECTIVES

Upon completion of this chapter, the reader should be able to:

- Illustrate and discuss the clinical anatomy of the periodontium.
- Illustrate and describe the microscopic anatomy of the periodontium.
- List and describe the functions of the periodontium.
- Discuss the importance of the dentogingival unit.
- Describe the lymphatic, blood, and nerve supply to the gingiva and the attachment apparatus.

GOAL: To provide knowledge of the structures and functions of the periodontium in health.

KEY WORDS

attachment apparatus	3	gingiva	3
biologic width	12	gingival crevice	4
col	5	junctional epithelium	8
connective tissue attachment	10	oral epithelium	8
dentogingival unit	12	periodontium	3
		sulcular epithelium	8

Introduction

The **periodontium**, translated in Latin to mean “around the tooth,” consists of the **gingiva**, periodontal ligament, cementum, and alveolar and supporting bone of the teeth (Figure 1–1a ■). The **attachment apparatus** consists of periodontal tissues involved in the attachment and support of the root in the tooth socket, specifically the periodontal ligament, cementum, and alveolar bone (Hassell, 1993). A working knowledge of the ultrastructural anatomy and biology of the periodontal tissues is an important prerequisite for practitioners to recognize and treat periodontal diseases.

To understand the different stages of diseases in the periodontium, it is necessary to recognize the structures and functions of the periodontium in health (Bartold, 2006). This chapter describes the clinical and microscopic features of the periodontium in health and will be the foundation for ensuing discussions in this text.

Clinical Anatomy of the Gingival Unit

The oral mucosa is divided into three types: (1) masticatory mucosa, which includes the gingiva and hard palate; (2) lining mucosa, which consists of the alveolar mucosa, soft palate, lining of lips, cheeks, and sublingual area; and (3) specialized mucosa, which is found on the dorsum of the tongue.

Masticatory Mucosa (Gingiva)

The gingiva forms a protective covering over the other components of the periodontium and is well adapted to protect against mechanical insults (e.g., toothbrushing and chewing). The gingiva encircles the cervical portion of the teeth and covers the alveolar process. Anatomically, the gingiva is subdivided into the free gingiva, attached gingiva, and interdental gingiva or papilla (Figure 1–1b). The outer surface of the gingiva consists of stratified squamous epithelium.

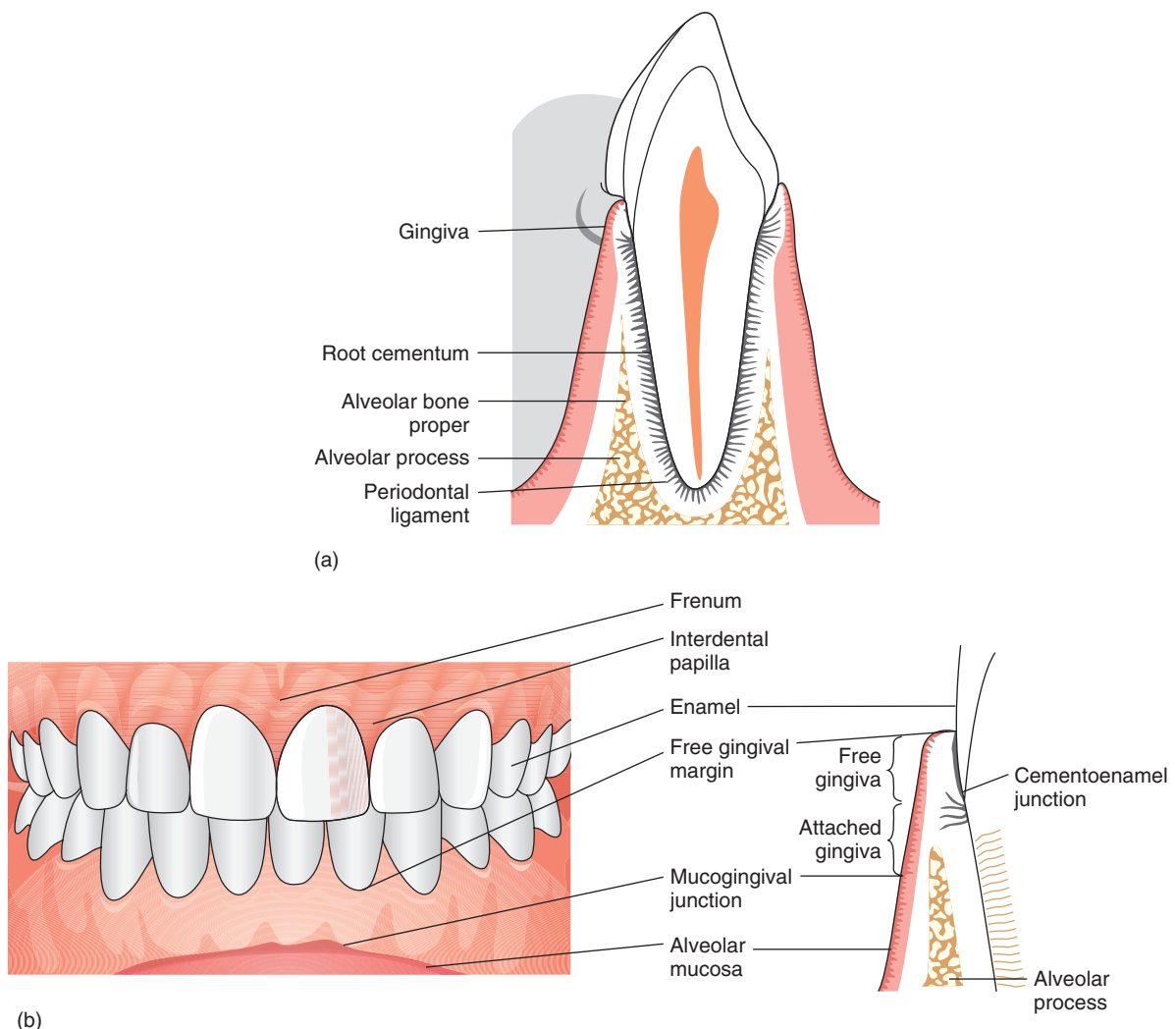


FIGURE 1–1 (a) Schematic drawing of a tooth with its periodontium. (b) Landmarks of the gingival unit. (Left) The gingiva is salmon pink, whereas the alveolar mucosa is thinner and redder in color. (Right) Schematic drawing of a cross-section of the periodontium.

Underneath the epithelium is gingival connective tissue, which is termed the lamina propria.

FREE GINGIVA (MARGINAL GINGIVA) The free gingiva, or marginal gingiva, surrounds the neck of the tooth. Its boundaries are, coronally, the free gingival margin; apically, the free gingival groove; and laterally, the gingival crevice and the tooth (see Figure 1–1b). The free gingiva is approximately 1.5 mm wide and has a smooth surface. The free gingiva lies on and adapts to the enamel and can be separated from the tooth with a periodontal instrument (Schroeder & Listgarten, 1997).

In health, the free gingival margin is the edge or the most coronal part of the free gingiva and in a fully erupted tooth is located on the enamel approximately 0.5 to 2 mm coronal to the cementoenamel junction (CEJ). In health and if teeth contact in the anterior region, the free gingival margin usually has a scalloped outline following the contour of the cementoenamel junction (see Figure 1–1b). If there is an open contact, the free gingival margin becomes blunted. In the posterior region, the architecture becomes less scalloped. Prior to the completed eruption of permanent teeth in children, the free gingival margin usually remains located on the cervical bulge of the enamel. This is a normal situation, and as the tooth erupts the free gingival margin will ultimately move apically.

Gingival Crevice. The **gingival crevice** is the space between the free gingiva and the tooth surface and is lined by nonkeratinized stratified squamous epithelium. In gingival health, the gingival crevice is termed a sulcus; once inflamed, it is termed a pocket. Healthy gingiva sulcular depth is approximately 1 to 3 mm when measured with a periodontal probe. Only in experimental conditions with germ-free animals can the sulcular depth be zero.

Gingival crevicular fluid (GCF) fills the sulcus, originates from blood vessels within the underlying connective tissue (lamina propria), and flows through the tissue into the gingival crevice. The rate of passage of this fluid is dependent on the absence or presence of inflammation in the connective tissue of the gingiva. The flow is minimal to absent in health, but increases due to inflammation from accumulation of plaque in the gingival crevice (Alfano, 1974). Components of GCF resemble blood serum components and include elements such as calcium, sodium, potassium, and phosphorus, along with cells and bacteria. The role of GCF is both protective and destructive. Although crevicular fluid flow cleanses the sulcus, it is also a source of nutrients for subgingival bacteria and supports subgingival calculus formation (Mukherjee, 1985). Certain antibiotics, including tetracyclines used in the treatment of periodontal diseases, have been found to concentrate in higher levels locally in the GCF (pocket area) than in the serum (Gordon, Walker, Murphy, Goodson, & Socransky, 1981).

Free Gingival Groove. The free gingival groove, a shallow depression on the outer surface of the gingiva, is about 1 to 2 mm apical from the margin of the gingiva and is slightly

Did You Know?

The gingival crevicular fluid (GCF), which bathes the gingival crevice subgingivally, contains many minerals and substances. Subgingival calculus is usually a dark color, such as black, due to the influence of GCF.

Rapid Dental Hint

It is important to transpose the patient's free gingival margin and mucogingival junction to the periodontal chart because this will help you determine if there is a soft tissue defect present and to monitor the attachment level and gingival recession.

apical to the level of the cementoenamel junction. This groove separates the free gingiva from the attached gingiva. The free gingival groove is present in about 30% to 40% of adults and occurs most frequently in the mandibular premolar and incisor areas. It is more pronounced on the facial than on the lingual regions. Its absence or presence is not related to the health of the gingiva.

ATTACHED GINGIVA The attached gingiva is continuous with the free gingiva and is firmly attached to the underlying cementum and periosteum (connective tissue) covering the alveolar process. It extends apically from the free gingival groove to the mucogingival junction (MGJ). If the free gingival groove is not present, then the landmark is at a horizontal plane placed at the level of the CEJ. The mucogingival junction joins the attached gingiva to the alveolar mucosa (see Figure 1–1b) except on the palate because the attached gingiva runs into the palatal mucosa. The width of the free gingiva and the attached gingiva consists of the total width of gingiva.

Attached gingiva is not movable, as it is bound down to the bone and cementum by connective tissue fibers, making it capable of withstanding forces from toothbrushing and chewing. The width of the attached gingiva varies in different areas of the mouth and between individuals (Figure 1–2 ■). On the facial aspect, the attached gingiva is widest in the incisor region and narrowest in the first premolar area. On the lingual aspect, the attached gingiva is widest in the molar region and narrowest in the incisor region.

The color of the gingiva is normally salmon pink with slight variations. The gingiva shows varying degrees of brownish-black color depending on ethnic variation

Did You Know?

Dogs, cats, and other animals also have gingiva, just like us.

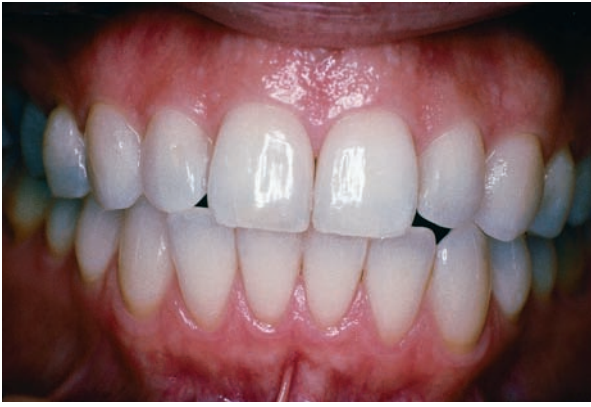

FIGURE 1-2 Varying amounts of attached gingiva; the narrowest width is on the mandibular premolars, and the widest is on the maxillary incisors.

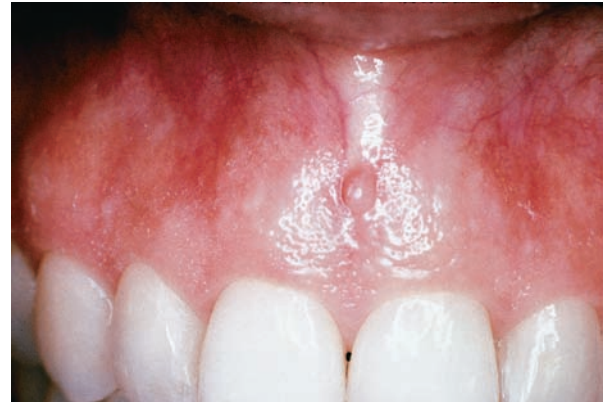

FIGURE 1-4 Surface stippling of the attached gingiva and the interdental gingiva. Note the dimpling or depressions on the surface. The surface of the free gingiva is not stippled.

(Figure 1-3 ■), which is considered to be normal gingival coloring and is referred to as melanin pigmentation.

Stippling. Clinically, the outer surface of the attached gingiva has an appearance similar to an orange peel with shallow depressions between elevations. The free gingiva has a

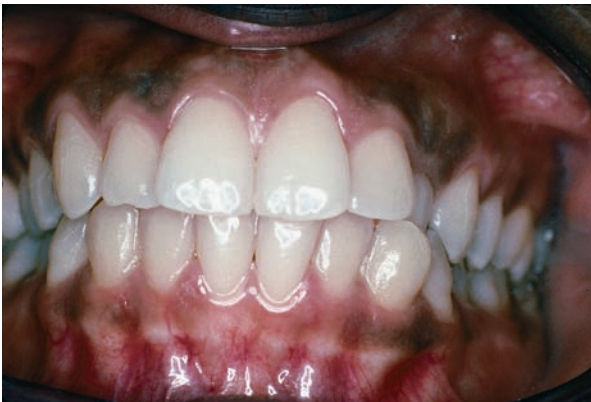smooth surface and is not stippled (Figure 1-4 ■). A histologic description of stippling is discussed in the following section.

Stippling may be present in health or disease. The absence of stippling does not necessarily indicate the presence of disease. On the other hand, the presence of inflammation with the loss of stippling can be considered part of the disease process, assuming stippling was present initially.

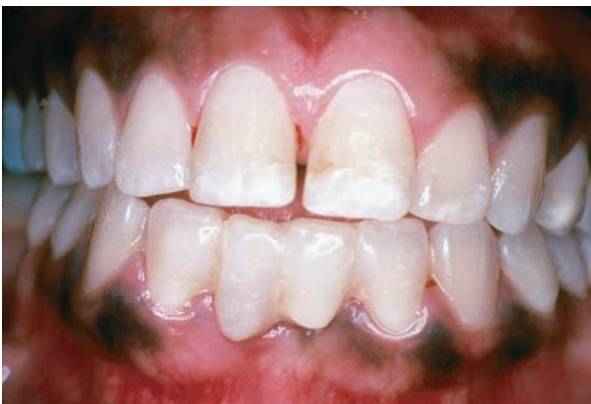Stippling is present in only about 40% of adults and varies in different individuals, ages, and sexes. Stippling of the attached gingiva is absent in children under 5 years of age and may be more evident in men than women. It is more prominent in the anterior than the posterior region and may even be absent in the molar areas. The facial gingiva shows more prominent stippling than the lingual.

INTERDENTAL GINGIVA (INTERDENTAL PAPILLA) In health the interdental gingiva tightly fills the gingival embrasure, which is the space between the contact point and alveolar bone of two adjacent teeth. The margin and lateral borders of the interdental gingiva are an extension of the free gingiva, whereas the remaining parts are attached gingiva (Figure 1-5 ■).

The size and shape of the papillae are determined by tooth-to-tooth contact, the curvature of the cemento-enamel junction, and the width (faciolingually) of the interproximal tooth surfaces. When teeth are crowded, often seen in mandibular incisors, the papillae may be slender and narrow. Anterior papillae are pyramidal in shape whereas posterior papillae are rounder and slightly flatter. An anterior papilla forms a single pyramidal structure because there is only one papilla. The papillae of posterior teeth (premolars and molars) are wedge shaped, with one vestibular (facial) and one oral (lingual) papilla connected by a concave area called the **col** (Figure 1-5). The col is directly apical to the contact area, representing the fusion of the interproximal junctional epithelia of two adjacent teeth. Although an anterior papilla can form a col shape, it is more prominent



(a)



(b)

FIGURE 1-3 (a) Physiological gingival pigmentation varies: light pigmentation. (b) darker, more pronounced pigmentation.

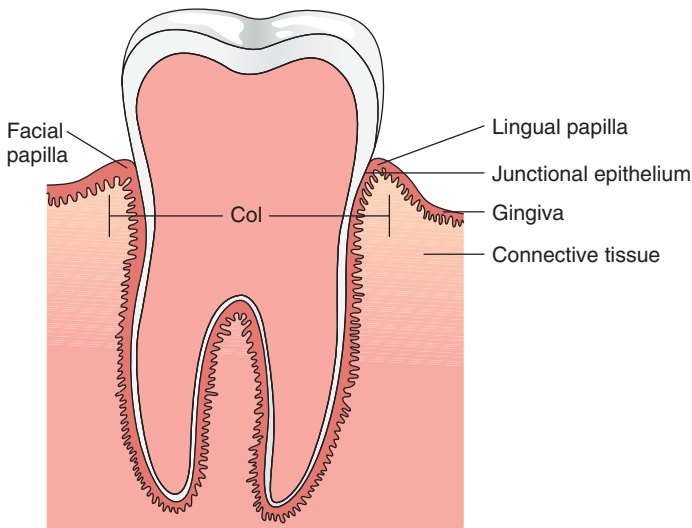


FIGURE 1-5 Features of the interdental gingiva. The col is directly under the contact area of the teeth.

Rapid Dental Hint

Remember that anterior teeth may have a small col or it may not be detectable.

in posterior papillae. When a diastema (loss of contact between two adjacent teeth) is present, the interdental papilla is absent, and there is no col. Because the shape of a col is concave and may not be keratinized, it may predispose the interproximal area to the accumulation of dental plaque.

Lining Mucosa

ALVEOLAR MUCOSA Although not actually part of the periodontium, the alveolar mucosa is an important periodontal structure and deserves discussion. The alveolar mucosa extends apically from the mucogingival junction to the mucous membrane of the cheek, lip, and floor of the mouth (see Figure 1-1b). In comparison to the attached gingiva, alveolar mucosa is thinner and redder in color, has a smooth surface, is movable, and is not keratinized.

FRENUM ATTACHMENTS Frenum (plural: frena) attachments are folds of alveolar mucosa. They are not concentrations of muscle, having no more muscle fibers than alveolar mucosa. The function of a frenum is to attach lips and cheeks to the maxillary and mandibular mucosa and to limit the movement of the lips and cheeks. There are usually seven frena located in the canine/premolar area, between the central incisors and in the mandibular anterior lingual area.

Did You Know?

Gingiva is salmon pink in color due to keratin. Keratin is a protein that is also involved in forming hair, skin, and fingernails.

Specialized Mucosa

The mucosa of the dorsum of the tongue contains numerous papillae of three types: filiform, fungiform, and circumvallate. The circumvallate papillae are located along the V-shaped groove on the back of the tongue. Each papilla is surrounded by a circular groove. The taste buds are located mainly on the sides of these papillae. The filiform papillae are slender ones and the most abundant, covering the entire top or dorsal surface of the tongue. No taste buds are associated with these papillae; they respond only to heat and mechanical stimuli. The fungiform papillae, which are broad and flat, are found chiefly at the edges of the tongue and are provided with taste buds.

Microscopic Anatomy of the Gingival Unit

Gingival Epithelium

The gingiva is covered by a layer of stratified squamous epithelium with an underlying core of connective tissue called the lamina propria (Figure 1-6 ■). The gingival epithelium exists as structurally different forms specific to certain areas of the teeth. Thus, the gingival epithelium can be divided into (Figure 1-7 ■) the following elements:

- The oral epithelium (OE)
- The sulcular or crevicular epithelium (SE)
- The junctional epithelium (JE)

The gingival epithelium is avascular and relies on the underlying lamina propria for its blood supply and nutrients. The epithelium found in the oral cavity consists of several layers of cells (see Figure 1-7):

- Stratum basale or stratum germinativum (basal cell layer); deepest layer next to the lamina propria.
- Stratum spinosum (spinous cell layer).
- Stratum granulosum (granular layer).
- Stratum corneum (keratinized/cornified cell layer; also called the superficial cell layer); this outermost layer serves as a barrier membrane protecting the underlying periodontal tissues from invasion by foreign substances.

CELL RENEWAL Just like the epithelium of the skin, the gingival epithelium is also subject to considerable insult and thus must have a means of regular renewal. The epithelium achieves this renewal by producing a pool of cells that migrate from the basal layer to the oral environment. This process by which epithelial cells differentiate or mature is

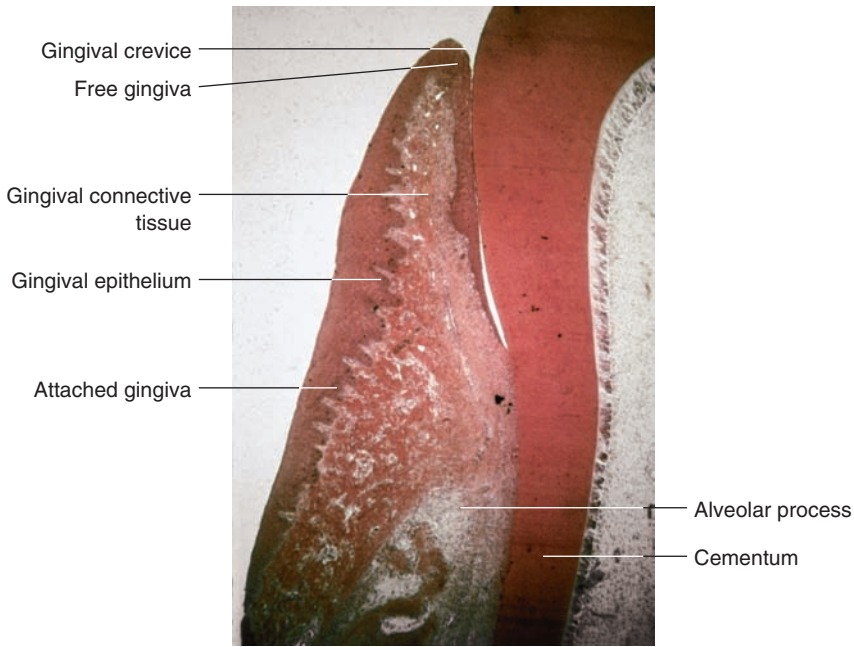


FIGURE 1-6 Photomicrograph of the gingival epithelium. (Courtesy of Dr. Harvey Wishe, New York University College of Dentistry.)

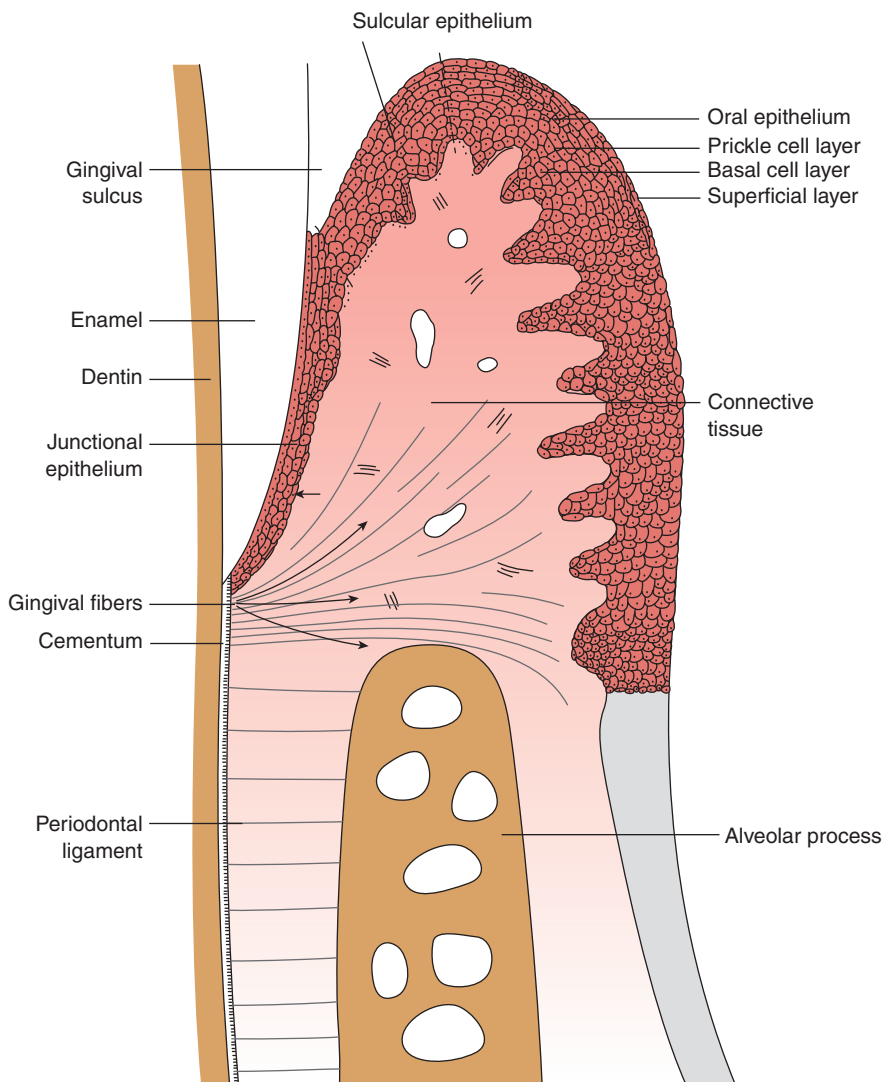


FIGURE 1-7 Diagram of the layers of the gingival epithelium. Underlying the epithelium is the gingival connective tissue (lamina propria).

called keratinization. The type of differentiation reflects the functional demands or stimulus placed on the tissue. During keratinization, the entire thickness of the epithelium is replaced. The time it takes for this replacement or cell renewal is called the turnover time. This time differs with the various types of epithelium. Such differences become important during tissue healing after periodontal surgery or tissue damage.

The keratinization process occurs as follows (Moss-Salentijn & Hendricks-Klyvert, 1990):

- Basal cells in the basal cell layer divide and produce new cells.
- The “older” basal cells travel or move into the next layer, the spinous cell layer, on their way to the most outer epithelial cell layer.
- Once in the spinous cell layer, the basal cells become keratinocytes. On their way to the outer surface, the keratinocytes synthesize or produce keratin.
- Keratin is a protein that contributes to the mechanical toughness of the outer surface of the epithelium.
- When the keratinocytes reach the outer epithelial surface, they are shed from the surface into the oral cavity.

Three grades of keratinization or maturation are identified according to the completeness of the transition of the keratinocyte from the basal cell layer to the outermost, superficial cell layer. Consequently, epithelium can be (ortho) keratinized, parakeratinized, or nonkeratinized. Keratinized epithelium is composed of all four layers and is primarily seen in the skin. Fully keratinized cells form keratin and lose their nuclei by the time they migrate to the outer surface. Findings show that 76% of the gingival exhibit parakeratin cells, which retain their nuclei but show some signs of being keratinized. The stratum granulosum is usually difficult to recognize, and a surface parakeratinized outer layer is present. Epithelial cells found in the junctional epithelium and alveolar mucosae are nonkeratinized and do not undergo keratinization.

ORAL EPITHELIUM The **oral epithelium** faces the oral cavity on the outer surface of the free and attached gingivae extending from the free gingival margin to the mucogingival junction. The gingiva is generally composed of parakeratinized stratified squamous epithelium, but can be orthokeratinized in small patches and in other species such as monkeys.

The gingiva has an epithelial turnover time of approximately 10 days as demonstrated in an animal model (Schroeder & Listgarten, 1997), whereas in the skin it is approximately 28 days.

Cells in the Oral Epithelium. The function of the oral epithelium is to protect the underlying structures and act as a mechanical barrier. The oral epithelium contains the following types of cells:

- Keratinocytes
- Nonkeratinocytes (also called clear cells)
- Melanocytes

- Langerhans cells
- Merkel cells
- Inflammatory cells (e.g., neutrophils)

Keratinocytes make up the majority of oral epithelial cells. Keratinocytes function to synthesize keratin, which contributes to the mechanical toughness of the outer surface of the oral epithelium and relative impermeability to fluids and cells. It is also responsible for the salmon pink color of the gingiva.

Melanocytes located in the basal cell layer secrete melanin, which is responsible for the brownish pigmentation in the gingiva. Pigmentation is more prominent in darker-skinned individuals (see Figure 1–3). The amount of pigmentation is genetically predetermined according to the potential of the cells to produce melanin, rather than to the number of cells present.

Other cell types in the gingival epithelium are the Langerhans cells, which are located in the stratum spinosum and are involved in the early defense mechanism of the gingiva. Merkel cells are found in the basal cell layer and are associated with nerve endings acting as touch-sensory cells. White blood cells such as lymphocytes and neutrophils or polymorphonuclear leukocytes (PMNs) are transiently found in the epithelial layers in health but increase in numbers in periodontal disease, functioning to defend the body against bacteria and other invaders.

SULCULAR EPITHELIUM The **sulcular epithelium** is structurally similar to the oral epithelium except that it is less keratinized. The sulcular epithelium exhibits good resistance to mechanical forces and is relatively impermeable (resistant) to the flow of fluids and cells. The sulcular epithelium may have epithelial ridges, or rete pegs, in health or disease, as does the oral epithelium, but to a lesser extent. Sulcular or crevicular epithelium lines the gingival sulcus without being attached to the tooth surface. It is generally nonkeratinized and thin but can become parakeratinized if exposed to the oral environment. The sulcular epithelium exhibits two or three cell layers, but a definitive and continuous cornified layer is absent. At the free gingival margin, the sulcular epithelium is continuous with the oral epithelium. Apically, it overlaps the coronal surface of the junctional epithelium (see Figure 1–7).

JUNCTIONAL EPITHELIUM The **junctional epithelium** is a band of epithelial cells that surrounds the tooth and creates a “seal” at the gingival crevice to hold it firmly in place. It is continuous with the free gingiva and provides the contact between the gingiva and the tooth. The junctional epithelium can be regarded as a down growth of the squamous epithelium of the gingiva and is continuous with the sulcular epithelium, extending from the bottom of the crevice to the cemento-enamel junction in health and in gingivitis; there is no loss of attachment. It forms a collar around the neck of the tooth on the cervical part of the enamel.

The junctional epithelium, through the epithelial attachment, contributes to the direct attachment of the

gingiva to the tooth surface and thus serves a significant role in periodontal health and disease when this attachment to the tooth is lost.

The junctional epithelium is composed of nonkeratinized stratified squamous epithelium. It is composed of only two epithelial layers, either an active basal cell layer and an inactive suprabasal cell layer or a basal cell and spinous cell layer (Hassell, 1993; Schroeder & Listgarten, 1997). The junctional epithelium in health has no rete ridges. When inflammation sets in, the junctional epithelium develops epithelial projections into the adjacent inflamed connective tissue.

At the coronal portion, the thickness of the junctional epithelium is about 15 to 30 cells, whereas apically, near the cemento-enamel junction, there may be only 1 to 2 cells (see Figure 1–7). Interproximally, the junctional epithelium of adjacent teeth fuses coronally to form the lining of the col area (Schroeder & Listgarten, 1997).

Semipermeable Membrane. The junctional epithelium is more permeable than the oral or sulcular epithelium. Thus, the junctional epithelium is referred to as a semipermeable structure, allowing the movement of bacterial products, fluids, and cells of certain sizes (Kornman, Page, & Tonetti, 1997). There are fewer intercellular junctions and thus wider spaces between the cells than in the oral or sulcular epithelium, and the cells are arranged in a parallel fashion. This allows for easy passage of cells and tissue fluid from the lamina propria into the sulcus and for passage of bacteria and its by-products from the gingival sulcus into the lamina propria. It is also more permeable because the cells do not keratinize. The coronal part of the junctional epithelium that is closest to the bottom of the sulcus is the most permeable part, whereas the apical part is where cell division for tissue renewal occurs.

Cells in the Junctional Epithelium. In addition to keratinocytes, the junctional epithelium may contain clear cells. In health, small numbers of PMNs are transiently seen in the junctional epithelium (Tonetti, Imboden, Gerber, & Lang, 1995). They will usually pass through the junctional epithelium into the gingival sulcus, where they play a role in the defense of the host (body) against bacteria and other microorganisms.

Cellular Turnover. A unique characteristic of the junctional epithelium is its high rate of cellular turnover. As demonstrated in an animal model, the cells of the junctional epithelium undergo constant turnover every 4 to 7 days,

whereby the basal cells migrate coronally out through the sulcus where the old cells are shed into the oral cavity.

Alveolar Mucosa

The alveolar mucosa is compressible and movable due to the presence of a submucosa between the thin lamina propria and the underlying tissue, usually muscle. The presence of elastic fibers, and an underlying loose connective tissue that is attached to the underlying periosteum of the alveolar process, also allows for movement.

The epithelium of the alveolar mucosa has about the same thickness as that of the gingiva, but its structure is completely different (Schroeder, 1991; Schroeder & Listgarten, 1997). A granular layer is not present, and the superficial layer does not histologically stain, as does the surface of parakeratinized epithelium (Squier & Hill, 1998). The epithelium contains melanocytes, Langerhans cells, Merkel cells, and small lymphocytes.

Epithelial ridges are usually not present; if present, they are indistinct because they are shorter and wider than in the gingiva, giving a smoother surface texture. The color is darker red than the gingiva because of its highly vascular underlying connective tissue. The point where there is a marked increase in elastic fibers within the underlying connective tissue demarcates the mucogingival junction.

Gingival Connective Tissue

Underlying the stratified squamous epithelium and encircling the tooth is the gingival connective tissue or lamina propria (Nanci & Bosshardt, 2006).

CONNECTIVE TISSUE/EPITHELIUM INTERFACE The interface between the connective tissue and oral epithelium is through connecting epithelial ridges that extend into the connective tissue (Figure 1–8 ■). At the intersection of epithelial ridges are pits or depressions that contain connective tissue extensions called connective tissue papillae. Clinically, these depressions may be evident on the surface of the gingiva, creating a stippled appearance. Stippling is established at the areas of fusion between adjacent epithelial ridges. In periodontal health the epithelial ridges are absent from the junctional epithelium and are not well developed in the sulcular epithelium. The main purposes of stippling are to aid in the increased strength between the epithelium and connective tissue and to enable the epithelium to obtain its blood supply from the connective tissue papillae in the shortest distance possible (Nanci & Bosshardt, 2006).

GINGIVAL CONNECTIVE TISSUE The main component of the gingival connective tissue, as with all connective tissue, is collagen fibers, accounting for about 60% of the total volume. Collagen is a protein composed of amino acids. There are many different types of collagen, with Types I (95%) and III (5%) found in gingival connective tissues. Type I collagen fibers give the gingiva its firmness and resiliency. The lamina propria provides mechanical support and nutrients

Did You Know?

The junctional epithelium is only three to four layers thick in early life but its thickness increases with age. The length of junctional epithelium is only about 0.25 to 1.35 mm. Just think about this—only about 1 mm long!